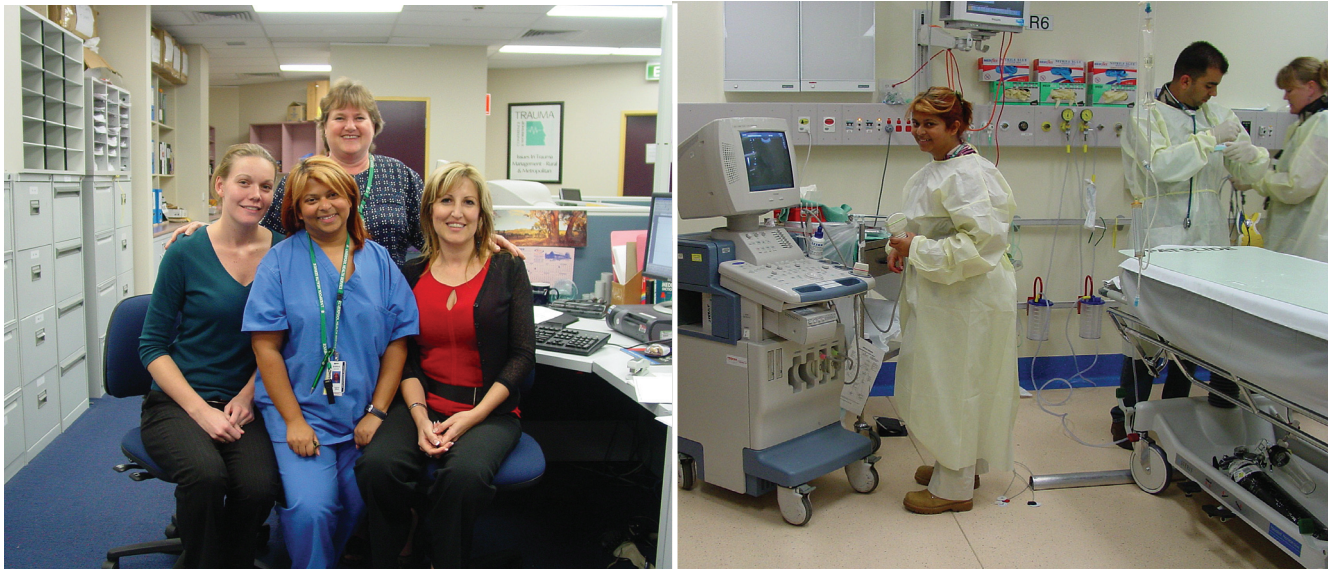

FAST scanning Down Under

Borsha Sarker

Borsha Sarker describes her weeks at Liverpool Hospital, Sydney as the 2005 ASUM BMUS exchange awardee



Borsha with the trauma secretaries at Liverpool and (right) Trauma call: preparing for a trauma arrival

Fancy a trip to Australia to learn more about medical ultrasound? That's what the advertisement said, and who would say no?

For the last two years at Queen Elizabeth Hospital in the UK, I have been training our accident and emergency (A&E) consultants in emergency ultrasound, which includes Focussed Assessment with Sonography for Trauma (FAST), ultrasound assessment of Abdominal Aortic Aneurysm (AAA) and ultrasound-guided line placements. Working with the A&E consultants exposed some training issues and challenges and we want to encourage all UK emergency department (ED) physicians to enrol in an approved FAST AAA course.

At the Queen Elizabeth Hospital, FAST and AAA ultrasound training takes place only on outpatients and some ward patients. Ideally, a proportion of this training should take place in the emergency room on real trauma patients. Few sonographers have wide experience of such situations and, therefore, find it difficult to train effectively. I wanted some practical experience of FAST.

To do this I needed to travel to Liverpool Hospital in Sydney, Australia, where FAST scanning is

widely used, to gain ultrasound experience in the emergency clinical setting, and to compare their training methods with ours. I hoped this would help me to support our ED physicians. I also wanted to explore how annual accreditation and maintenance of ultrasound skills is achieved and, hopefully, return home with some recommendations for a robust system of training physicians and a credentialling system that could be introduced regionally, if not nationally.

The good thing about the ASUM and BMUS Australian Exchange Award is that it aims to promote a 'short program of learning'. I had worked previously in Sydney (1993–1995) and had some professional contacts, lots of friends to help me and some idea of the cost. I applied to visit the Trauma Department at Liverpool Hospital in South-West Sydney. It is renowned internationally for its expert practice and innovation, sees large numbers of trauma patients and is the source of many publications and textbooks. We wanted to develop local clinical networks at home, but also foster links with our own trauma unit and the unit at Liverpool Hospital.

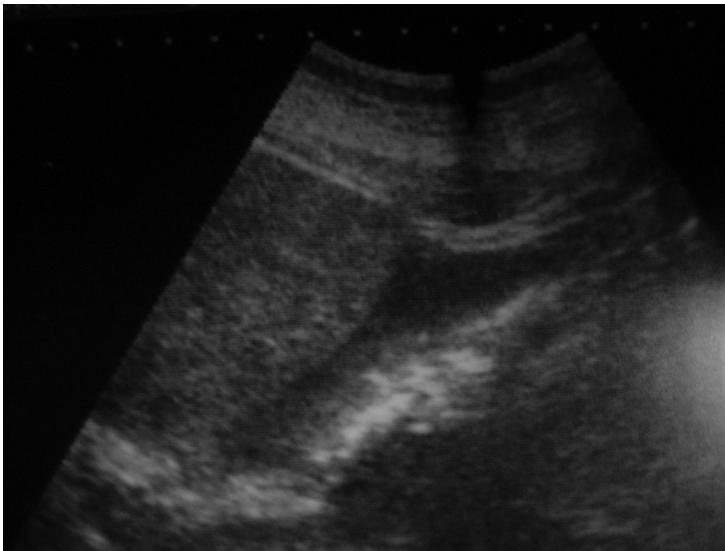I wrote to the Director of Liverpool Trauma Department, Dr Michael

Sugrue, and explained that I wanted to see exactly how, when and why FAST scanning was used in real trauma. Liverpool Hospital is relatively unusual as it serves a large geographical area and, due to the locality, sees a large amount of both blunt and penetrating chest and abdominal trauma. I was told that ultrasound is used in approximately 80% of trauma calls. They have a number of years of experience in FAST scanning in the ED Resuscitation Room (Resus).

A FAST scan involves four key spot views:

- i) hepato-renal angle and Right Upper Quadrant (RUQ);
- ii) spleno-renal angle and Left Upper Quadrant (LUQ);
- iii) pelvis in two planes; and
- iv) pericardium (sub-xiphoid or parasternal view).

Back home, when our ED physicians first approached radiology to train them, our instinctive reaction was to say no. We thought they would rampage unchecked into our territory, resulting in untold numbers of unnecessary investigations. Eventually, we did agree, on the condition that they enrolled on a focussed emergency ultrasound course, offered by our local university at Teesside and limited their



FAST scan in Resus



Borsha Sarker with Caroline Hong at ASUM headquarters

practice to the agreed areas in which they would receive training. The course gave them the underpinning theory. We provided the practical tuition and mentoring during their training.

Initially, they were required to complete 35 hours. This was achieved by visiting radiology for one morning per week. We started off trying to teach them as we would a student sonographer or radiology registrar. After a few weeks, we could see this approach was slow and failing to give rapid results. We then concentrated on only obtaining the five views of the pericardium, RUQ, LUQ, pelvis and aorta. While this was more effective, it was still difficult to get suitable patients with pathology from which to learn. At 30–35 hours, while the ED physicians were confident with their views and could identify more obvious pathology in easier subjects, they still struggled with more subtle pathology and difficult subjects. We advised that the number of required practical hours be increased to 60 or 100 cases for them to be competent and confident.

I, therefore, found it difficult to understand how a one-day course could produce competent FAST practitioners as is claimed in the Australian and American literature. This is one of the reasons why I wanted to see practice in Australia and see whether and where we were going wrong in Gateshead. I also wanted to see if we could make any recommendations for FAST training in the UK and wanted some experience in the Resus room, so that I could pass this on to my FAST students.

Before departing for far-off Australia, I completed arrangements

with the Liverpool Hospital, ran the gauntlet of Australian Immigration, obtained a working visa, and completed security and criminal record background checks (maybe they don't accept convicts anymore?). The trip over was fine and, after a few days holiday to get over the jetlag, I was ready for work. I wasn't sure what to expect from my first day.

I was given an office (fantastic – I don't even have one at home), my own PC, a pager, hospital ID and access tags to the secure parts of the hospital that I would need to get to or through at night. Dr Sugrue had a program prepared for me, in addition to my own agenda, and introduced me to the Trauma and ED staff during an orientation on my first morning. This was invaluable.

In many places, FAST has replaced diagnostic peritoneal aspiration (DPA). DPA is used to detect gross blood in the abdomen of a trauma patient and if gross aspiration is negative, smaller amounts of blood can be detected using lavage fluid and microscopic red blood cell counts. This diagnostic peritoneal lavage (DPL) can be sensitive enough to detect amounts of blood as small as 20 mL. However, both DPA and DPL are invasive tests with their own associated morbidity (wound infections and a small risk of perforated bowel or bleeding if a blood vessel is punctured).

DPA/DPL are carried out by inserting a catheter into the peritoneal cavity, between the umbilicus and the symphysis pubis and aspirating to determine if there is gross haemoperitoneum (the DPA) followed by the infusion of 1 L

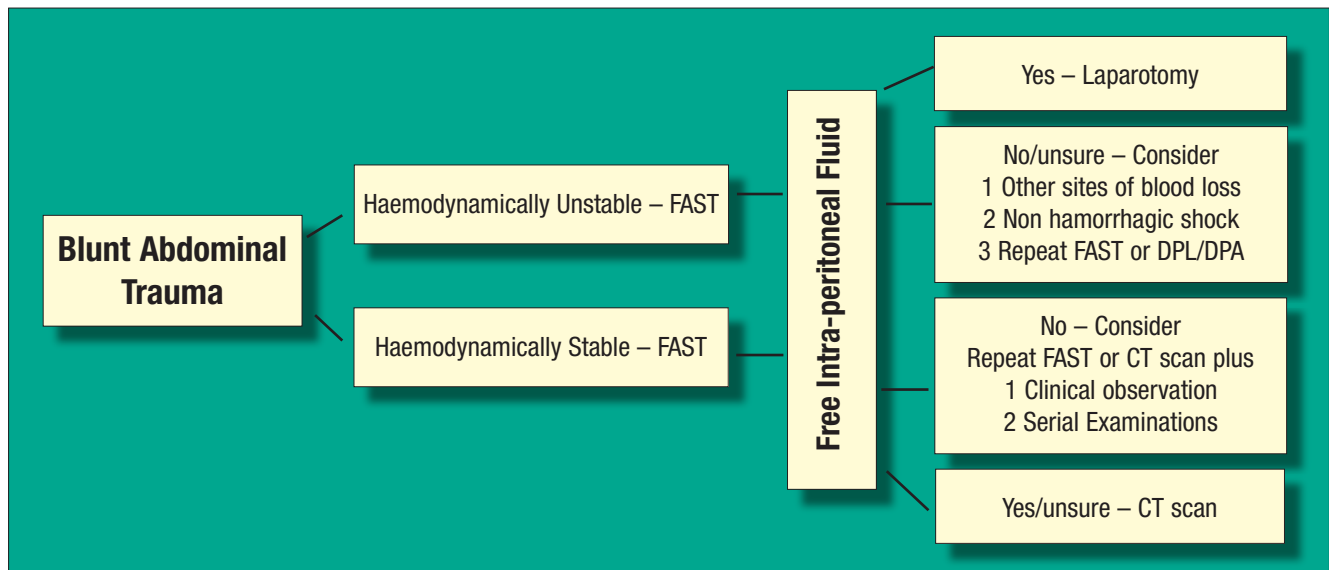
of saline, aspiration of the mixed peritoneal and lavage fluid (the DPL) and the sending of this fluid to the lab for analysis. This requires a significant level of surgical skill and cannot be repeated. It has very high sensitivity, but low specificity with an associated false negative rate (between 3 and 5%) and false positive rate due to misplacement of the catheter. If one were to use the red blood cell count one would end up with a 30% non-therapeutic laparotomy rate.

FAST has obvious advantages as it is quick, non-invasive and can be easily repeated. It is most useful in haemodynamically unstable patients as a quick way of screening the abdomen as a source of major haemorrhage in the multi-trauma patient, but also in the penetrating chest injury patient, to assess for the presence of fluid in the pericardium. It is sensitive to small amounts of free fluid (probably 20–50 mL), but this is more operator dependent and not always reliable.

Learning the technique is reported to be relatively easy, with a steep initial learning curve, but ongoing accuracy is dependent on sufficient practice and ongoing quality assurance. One can see why it is so attractive clinically for trauma surgeons and emergency physicians. The potential problems we found in our UK practice were associated with the credentialling process and ensuring ongoing competency of the operators, so that the test remains useful.

In general, trauma care in Australia is more systematically organised than in the UK. Australian catchment areas are larger and, therefore, more





Basic algorithm for FAST in the diagnostic pathway for blunt abdominal trauma

episodes of severe trauma per individual emergency physician are seen. This is why, we have provided the bulk of our training within radiology at my hospital. I was concerned that the pathology we see in patients from the ward could present and look quite different in the trauma situation and was worried as to how transferable the skills we were teaching would be.

I started watching some trauma calls and gradually helped out more. I was at Liverpool for 19 days and in that time there were 58 trauma calls. I attended almost 50 of these, including night and weekend calls. At least 40 calls had a FAST performed and seven of these were positive – two for abdominal blood and five for chest fluid. While I took very few hours off I, typically, managed to miss the only two positive abdominal FAST scans, both liver ruptures.

Some FAST cases, involving unstable patients, were very useful to observe even though the FAST was negative. One patient had two negative FAST scans before the source of bleeding was found elsewhere (vascular limb injury). While our ED physicians would say that they would not rely on a negative FAST scan for a final diagnosis (a worry for radiology), it was clearly useful to help decision making while a patient was being stabilised i.e. theatre, immediate Computerised (Axial) Tomography (CT) or delayed CT after stabilising the patient (Ollerton, *et al. Journal of Trauma* 2006 60 (4): 785–791).

The CT scanner is colloquially known as the 'tunnel of death' as it is a place that no-one wants to be caught

out with an unstable trauma patient. Although one could argue that FAST scans are unnecessary as most patients need CT anyway and this should be based on good clinical examination and decision making, most ED staff would want to know that a CT was needed and that they had chosen the optimum time to take the patient to x-ray i.e. when stable and alternative sources of bleeding had been excluded. The most useful part of my visit was to experience 'life on the other side' and understand the clinical scenarios where FAST in use. Some of the patients are already intubated and ventilated with a soft abdomen and any clinical signs indicating abdominal injury are masked by anaesthetic agents.

At Liverpool Hospital, the result of a FAST scan can only be used if it is carried out by or supervised by an accredited member of staff. The trauma team is largely made up of a skeleton team of more junior staff at night and on weekends, and I saw that FAST was clearly a benefit at these times. When I attended some trauma calls, I was the only FAST accredited member of staff present and this allowed juniors to attempt a FAST under supervision that they would otherwise not have tried. I was able to fulfil this role during my visit, which allowed some of the juniors to rapidly accumulate a few supervised scans for their logbooks and accreditation process.

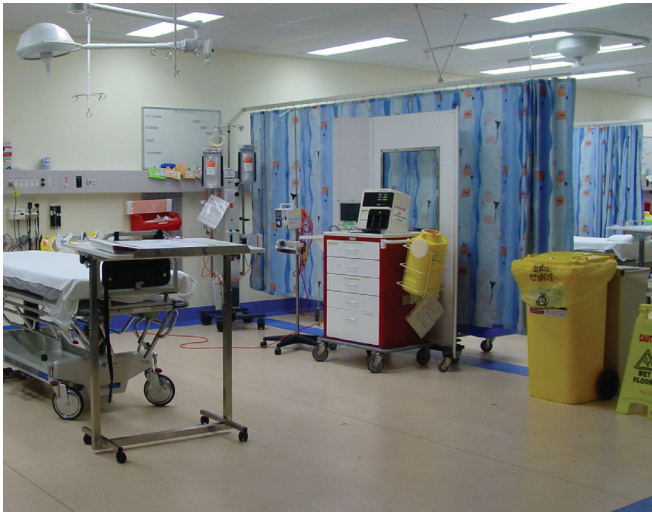The routine incorporation of FAST into the trauma survey allows training to occur and more confidence in juniors when the scan is really clinically indicated. This is something I

could see the value of as a direct result being there. However, the accumulation of cases is a lengthy task for the ED junior staff and there is clearly a need for more accredited staff.

I also identified some new personal training needs, e.g. basic echo training, as I found the para-sternal cardiac view was more reliably obtained than the sub-xiphoid view on emergency patients. I learned from assisting junior doctors in Resus, the practical pitfalls that I usually avoid without thinking by making my own small adjustments. Once I learned how to describe what I was doing, this clearly helped the juniors and some tips were even found useful by the experienced and long accredited emergency physicians.

While I was at Liverpool Hospital I also did some ultrasound training sessions with the trauma fellows and ED registrars. However, I realised that my visit was just too short to be able to finish all that I would have wished. My main regret is that I did not ask for a longer attachment. A visit of even six weeks would probably have yielded a few more positive scans. However, after three weeks of being almost constantly on-call, sleep deprivation may have stopped me first.

I have to say that I learnt a tremendous amount from the Trauma and ED staff who are immensely patient, helpful and made me feel at home. I could not have asked to work with a nicer bunch of people and had an absolutely fantastic time. Especial thanks would have to go to Michael Sugrue, Scott D'Amours, Justin Bowra, Alvaro Manovel, Erica Caldwell, Sally Horder,



The major trauma resuscitation bay in the Emergency Department at Liverpool Hospital

Thelma Allen and all the nursing and medical staff in the ED, who were great.

My thanks formally to the Trauma Department and Emergency Department of Liverpool Hospital for accepting me as a visitor for three weeks and also to Dr Caroline Hong and ASUM.

During my stay I visited the ASUM headquarters in Willoughby and Caroline, your CEO, kindly treated me to lunch. I hope my enthusiasm came across for the work I was doing, the lessons I was learning and the opportunity that I had been given by ASUM and BMUS.

Caroline put me in touch with Dr Tony Joseph at the Royal North Shore Hospital and I was lucky enough to attend and help out at one of his courses on emergency ultrasound, provided for the Australian military, assisted by SonoSite. This was a valuable experience because of my interest in effective training methods for FAST and I would like to extend my thanks to Tony and his staff, who were very welcoming.

After my experiences in Australia, I most highly recommend the ASUM and BMUS Australian Exchange Award scheme to anyone considering undertaking the opportunity of a 'short program of learning'. The pity is it was too short and there was so much to learn. Thank you BMUS; thank you ASUM; thank you Liverpool Hospital.

ASUM HEAD OFFICE IS MOVING

**OUR NEW ADDRESS WILL BE:
ASUM Head Office
Level 2
511 Pacific Highway
St Leonards NSW 2065
SYDNEY AUSTRALIA**

Details of move dates and new phone and fax numbers will be announced on the ASUM website
www.asum.com.au



**18-20 May 2007 Sydney
Convention & Exhibition Centre**

**The 14th National Conference of the
Australian Sonographers Association**

**Join us in Sydney for the largest
annual education and networking
meeting of sonographers in Australia.**

Consider proffering a paper or poster for your chance to win up to \$750. Online submission of abstracts closes Friday 23 February 2007.

Online registration available from 1 December 2006.

Early bird registration closes Friday 16 March 2007.

**For further information
please contact:**

**Australian
Sonographers
Association
National Office
PO Box 709
Moorabbin
VIC 3189**

P: 03 9585 2996

F: 03 9585 2331

E: cpd@A-S-A.com.au

